

Content available at: <https://www.ipinnovative.com/open-access-journals>

Indian Journal of Clinical Anatomy and Physiology

Journal homepage: <https://www.ijcap.org/>

## Original Research Article

## An osteological study of the clavicular facet of the coracoclavicular joint

Sulochana Sakthivel<sup>1\*</sup>, Nithya Dhakshnamoorthy<sup>1</sup>, Ilankathir Sridharan<sup>2</sup>, Sarala Devi K V<sup>3</sup><sup>1</sup>Jawaharlal Institute of Postgraduate Medical Education and Research, Puducherry, India<sup>2</sup>Aarupadai Veedu Medical College, Puducherry, India<sup>3</sup>ESI Medical College and Hospital, Chennai, Tamil Nadu, India

## ARTICLE INFO

## Article history:

Received 28-06-2024

Accepted 04-07-2024

Available online 20-07-2024

## Keywords:

Coracoid process

Conoid tubercle

Scapula

Clavicle

## ABSTRACT

**Background:** The coracoclavicular joint is a rare diarthrotic synovial joint between the scapula and clavicle. Its presence has been established as an etiological factor in shoulder pain and could be associated with upper limb paraesthesia. The incidence of the joint varies in different ethnic populations. The present study aims to report the prevalence of this joint in South Indians.

**Materials and Methods:** The descriptive study was conducted on 118 right-sided and 159 left-sided adult human dried clavicles. The conoid tubercle of the clavicles was examined for the presence of a smooth articular facet for the coracoid process of the scapula. The transverse and anteroposterior dimensions of the clavicular facet were measured using a digital Vernier caliper.

**Results:** The clavicular facet for the coracoclavicular joint was observed in 4.69% of the 277 bones. The shape of the facet was horizontally oval, and the transverse diameter was longer than the anteroposterior diameter. The mean transverse diameter was  $8.81 \pm 1.86$  mm, and the anteroposterior diameter was  $6.16 \pm 2.39$  mm.

**Conclusion:** With a prevalence of 4.69% in this study in the South Indian population, the presence of CCJ could not be considered a rare anomaly. Although it is incidentally diagnosed, the possibility of CCJ occurrence should be considered in the differential diagnosis of unexplained shoulder pathology.

This is an Open Access (OA) journal, and articles are distributed under the terms of the [Creative Commons Attribution-NonCommercial-ShareAlike 4.0 License](https://creativecommons.org/licenses/by-nc-sa/4.0/), which allows others to remix, tweak, and build upon the work non-commercially, as long as appropriate credit is given and the new creations are licensed under the identical terms.

For reprints contact: [reprint@ipinnovative.com](mailto:reprint@ipinnovative.com)

## 1. Introduction

The coracoclavicular joint (CCJ) is a diarthrotic synovial joint present between the conoid tubercle of the clavicle and the superior surface of the horizontal part of the coracoid process of the scapula.<sup>1</sup> In humans, its occurrence is rare, whereas it is evident in primates. The joint has a capsule, synovial lined space, and hyaline articular cartilage that covers the facets on the coracoid and the clavicle close to the subclavius groove.<sup>2</sup> Though the coracoclavicular joint is often disregarded as a structure without any significance,

its presence has been established as an etiological factor in shoulder pain, and it could be associated with upper limb paraesthesia.<sup>3–5</sup>

This joint was first described by Gruber in 1861.<sup>6</sup> During development, the cartilaginous procoracoid connects the coracoid process to the clavicle. The procoracoid ultimately forms the coracoclavicular ligament, which usually contains chondrocytes and cartilaginous nodules. The conoid tubercle of the clavicle and coracoid process occasionally grow toward each other, forming a joint covered by a capsule.<sup>7</sup> This joint was found to be more prevalent in Asians than in the other races.<sup>8</sup> In osteological studies, the prevalence ranged between 0.7% and 10%,

\* Corresponding author.

E-mail address: [sulo.ss@gmail.com](mailto:sulo.ss@gmail.com) (S. Sakthivel).

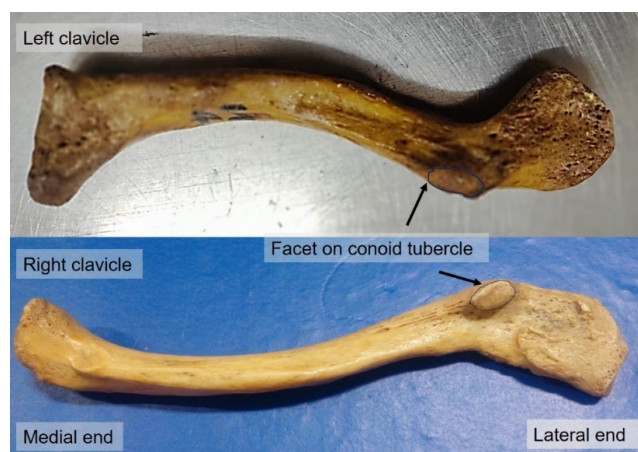
and in the radiological studies it was between 0.6% and 21%.<sup>9</sup> A higher prevalence of 1.7% to 30% was observed in cadaveric dissections due to the presence of articular cartilage and capsule.<sup>9–11</sup> Thus, the incidence of CCJ shows wide variation according to the type of study. The present study was undertaken to determine the prevalence of the articular facet on the conoid tubercle of the clavicles in the South Indian population.

## 2. Materials and Methods

The study was conducted on 277 adult human dry clavicles (118 right and 159 left) of undetermined sex that were available in the Department of Anatomy, ESI Medical College, after excluding the damaged bones. These bones were accessible for undergraduate teaching during the study period of 2018–2022. The occurrence of a smooth articular facet present on the conoid tubercle determined the presence of CCJ. The maximum transverse diameter and anteroposterior diameter of the articular facets were measured using a digital Vernier caliper. The parameters were analyzed using SPSS software version 20 (IBM Corp. Armonk, NY).

## 3. Results

The prevalence of CCJ was 4.69%. On the left side, it was observed in 10 bones, and on the right side, in three bones. The shape of the facet was horizontally oval, and the transverse diameter was longer than the anteroposterior diameter (Figure 1). The mean transverse diameter was  $8.81 \pm 1.86$  mm, and the anteroposterior diameter was  $6.16 \pm 2.39$  mm. On the right, it was  $10.82 \pm 1.6$  mm and  $8.06 \pm 1.09$  mm, respectively, and on the left, it was  $8.21 \pm 1.51$  mm and  $5.60 \pm 2.41$  mm, respectively. The differences between the right and left sides were not statistically significant.



**Figure 1:** Shows the clavicular facet on the conoid tubercle of the clavicle (inferior view)

## 4. Discussion

The coracoclavicular joint is a rare synovial joint with articulation between the conoid tubercle of the clavicle and the superior surface of the horizontal part of the coracoid process of the scapula. In radiological studies, the CCJ was determined by the presence of triangular bony outgrowth near the conoid tubercle. However, slight axial rotation of the clavicle while taking an X-ray will exaggerate the conoid tubercle, which could be mistaken for CCJ. A cadaveric study is more reliable because the presence of the articular capsule and cartilage confirms the CCJ, although the sample size might be small. Nevertheless, the dry bone study provides a large sample size to identify the facet on the clavicle or the coracoid process of the scapula.<sup>11</sup>

Gruber studied 350 cadavers and observed CCJ in eight specimens.<sup>6</sup> Gumina et al. observed CCJ in eight dry bones (0.78%) among 1020 clavicles.<sup>8</sup> In a radiological study on 1040 individuals from Northern India, the reported prevalence was 3.37%.<sup>17</sup> An osteological study from India demonstrated an increased prevalence of 5.6%,<sup>16</sup> whereas, in the adult Nigerian population, the prevalence was 0.55%.<sup>15</sup> In a radiological study, it was observed in 0.82% (18 individuals) of the 2192 individuals examined, and in their osteological study on 392 skeletons, the incidence was 1.78%.<sup>10</sup> Thus, CCJ has been studied using radiological, cadaveric, and osteological methods with differences in rate of prevalence. Many studies found the clavicular facet to be oval with a long horizontal axis followed by a circular shape.<sup>10,12</sup> The size of the facet in the study by Kaur and Jit ranged between 8 x 6 mm and 17 x 9 mm.<sup>12</sup> In the present study, the size ranged between 4 x 6 mm and 11 x 6 mm.

The geographical distribution and prevalence of CCJ in various studies in the literature are shown in Table 1. The occurrence of CCJ is observed to be higher in Asia than in Western Europe, particularly in people of Chinese ancestry, which confirms geographical variations in its existence.<sup>13</sup> Several studies reported that CCJ was more prevalent in males.<sup>12,14,17</sup> The incidence of clavicular facet was 10.1% in males and 8.3% in females in Northwest India.<sup>12</sup> Similarly, Nalla and Asvat also found the CCJ to be more prevalent in males (56.5%) than females (43.5%) in the South African population.<sup>14</sup> CCJ was found to be more common on the left side,<sup>17</sup> and the same was observed in the present study.

The incidence is also found to be higher in people above 30 years of age.<sup>19</sup> Paparoidamis et al. observed a higher incidence of CCJ (13.9%) in individuals more than 76 years of age than in those between 61–75 years of age (3.7%).<sup>18</sup> Likewise, in South Koreans, the joint was observed in 9.5% of the age group between 40–49 years and 11.4% of those aged 60 years.<sup>2</sup> In individuals below 40 years of age, the CCJ was not found, suggesting that the occurrence could be due to ageing.<sup>2</sup> However, CCJ has also been reported in children. Nehme et al. observed CCJ in a 5-year-old and a 7-year-old child.<sup>10</sup> Similarly, Kaur and Jit observed CCJ

**Table 1:** Geographical distribution and differences in the prevalence of CCJ in different modes of study

Study	Population	Sample size	Prevalence	Type of Study
Kaur and Jit <sup>12</sup> 1991	Northwest Indian	1000	18.4%	Osteology
Cockshott <sup>13</sup> 1992	Chinese	600	21%	Radiology
Nalla and Asvat <sup>14</sup> 1994	South African	240	9.6%	Osteology
Gumina et al. <sup>8</sup> 2002	Italian	1020	0.8%	Osteology
Nehme et al. <sup>10</sup> 2003	France	2192	0.82%	Radiology
Joy et al. <sup>15</sup> 2008	Nigerian	784	1.78%	Osteology
Das et al. <sup>16</sup> 2016	Indian	1637	0.55%	Radiology
Chopra et al. <sup>17</sup> 2017	North Indian	144	5.6%	Osteology
Paparoidamis et al. <sup>18</sup> 2018	Greece	1040	3.37%	Radiology
		216	6.5%	Osteology
Harlow et al. <sup>19</sup> 2021	African American	2724	12%	Osteology
	Caucasian		6%	
	American			
Present study 2024	South Indian	277	4.69%	Osteology

in a 13-year-old child but none in neonates or fetuses.<sup>12</sup> Thus, they concluded that environmental factors such as activity could not play a role in its occurrence, and it could not be a congenital anomaly as well. Although it was assumed to be an autosomal dominant trait, there was no genetic evidence.<sup>20</sup> According to Saunders, the CCJ does not follow the Mendelian pattern of inheritance. Despite sharing the same genetic makeup, individuals may or may not exhibit the trait. A physiological threshold determines whether the phenotype will be expressed or discontinued, and individuals will manifest the trait only when the threshold is crossed.<sup>21</sup> Furthermore, the genetic cause could not be ruled out because of the variations observed in the prevalence of CCJ between different races.<sup>13</sup>

Although some authors say that there is no relation between the presence of the CCJ and the size of the clavicle and scapula, Nalla et al. observed an increase in the size of neighbouring bones. They observed longer first ribs and lengthened superior, medial, and lateral borders of the scapula with a significant increase in superior angle and proposed that CCJ develops to compensate for the space restrictions caused by the long and narrow scapula with normal thoracic inlet size, which could cause restriction of scapular movements.<sup>14</sup> The presence of a CCJ in patients may present as thoracic outlet syndrome.<sup>22</sup>

Degenerative changes in the CCJ could be one of the causes of painful shoulders.<sup>4</sup> CCJ could also predispose to the development of degenerative changes in other neighbouring joints, such as the acromioclavicular joint.<sup>9</sup> Cheung et al. studied the microscopic structure of a resected CCJ and observed that the facet on the coracoid process had fibrocartilage lining, resembling the repair tissue following cartilage injury. In contrast, the clavicular facet was lined by mature hyaline cartilage.<sup>3</sup> Thus, the presence of CCJ has been established as an etiological factor in shoulder pain and could be associated with upper limb paraesthesia as

well.<sup>3,4</sup> Shoulder pain due to the confirmed presence of CCJ by imaging could be managed conservatively or by surgical resection depending on the severity of symptoms.<sup>3</sup>

## 5. Conclusion

In the South Indian population, with a prevalence of 4.69% in this study, the presence of CCJ could not be considered a rare anomaly. Awareness of the CCJ is essential in diagnosing and managing shoulder pain. Even though it is usually asymptomatic and incidentally diagnosed, the possibility of CCJ occurrence should be considered in the differential diagnosis of unexplained shoulder pathology.

## 6. Sources of Funding

None.

## 7. Conflict of Interest

None.

## Acknowledgements

"The authors sincerely thank those who donated their bodies to science so that anatomical research could be performed. Results from such research can potentially increase mankind's overall knowledge which can then improve patient care. Therefore, these donors and their families deserve our highest gratitude."

## References

1. Paraskevas G, Stavrakas ME, Stoltidou A. Coracoclavicular joint, an osteological study with clinical implications: a case report. *Cases J.* 2009;2:8715.
2. Cho BP, Kang HS. Articular facets of the coracoclavicular joint in Koreans. *Acta Anat (Basel).* 1998;163(1):56–62.
3. Cheung TF, Boerboom AL, Wolf RF, Diercks RL. A symptomatic coracoclavicular joint. *J Bone Joint Surg Br.* 2006;88:1519–20.

4. Nikolaidis AP, Dermon AR, Papavasiliou KA, Kirkos JM. Coracoclavicular joint degeneration, an unusual cause of painful shoulder: a case report. *Acta Orthop Belg.* 2006;72:90–2.
5. Willekens I, Maeseneer MD, Boulet C, Verhelle F, Mey J. Coracoclavicular joint with shoulder pain. *J Belgian Soc Radiol.* 2013;96(1):44. doi:10.5334/jbr-btr.190.
6. Gruber W. Die Oberschulterhakenschleimbeutel. In: Mémoires de l'Académie impériale des sciences de St.-Petersburg: L'Académie; 1861. p. 1–38.
7. DeHaas WHD, Kingma MJ, Drucker DF, F D. The coracoclavicular joint and related pathological conditions. *Ann Rheum Dis.* 1965;24:257–66.
8. Gumina S, Salvatore M, Santis PD, Orsina L, Postacchini F. Coracoclavicular joint: osteologic study of 1020 human clavicles. *J Anat.* 2002;201(6):513–9.
9. Singh VK, Singh PK, Trehan R, Thompson S, Pandit R, Patel V. Symptomatic coracoclavicular joint: incidence, clinical significance and available management options. *Int Orthop.* 2011;35(12):1821–6.
10. Nehme A, Tricoire JL, Giordano G, Rouge D, Chiron P, Puget J. Coracoclavicular joints. Reflections upon incidence, pathophysiology and etiology of the different forms. *Surg Radiol Anat.* 2004;26(1):33–8.
11. Williamson MA. A review of the coracoclavicular joint: Description, etiology, and clinical significance. *Clin Anat.* 2023;36(5):715–25.
12. Kaur H, Jit I. Brief communication: coracoclavicular joint in Northwest Indians. *Am J Phys Anthropol.* 1991;85(4):457–60.
13. Cockshott WP. The geography of coracoclavicular joints. *Skeletal Radiol.* 1992;21:225–7.
14. Nalla S, Asvat R. Incidence of the coracoclavicular joint in South African populations. *J Anat.* 1995;186(Pt 3):645–9.
15. Joy OE, Oladipo GS, Eroje MA, Edibamode IE. Incidence of coracoclavicular joint in adult Nigerian population. *Sci Res Essays.* 2008;3:165–7.
16. Das SS, Mahajan A, Vasudeva N. Morphometric Study of Clavicular Facet of Coracoclavicular Joint in Adult Indian Population. *J Clin Diagn Res.* 2016;10(4):8–11.
17. Chopra J, Rani A, Bajpai P, Manik P. Prevalence of coracoclavicular joint in northern India: Radiological evidence. *JCDR.* 2017;11:1–4.
18. Paparoidamis G, Trentzidis T, Otountzidis K, Piagkou N, Natsis M, K. Coracoclavicular joint: clinical significance and correlation to gender, side and age. *Anatomy.* 2018;12:57–60.
19. Harlow ER, Sasala LM, Talbot CE, Desai BJ, Ina J, Miskovsky S. Prevalence and Morphology of the Coracoclavicular Joint: An Osteological Study of 2,724 Subjects Using Univariable and Multivariable Logistic Regression Analyses. *Front Surg.* 2021;8:761441.
20. Pillay VK. The coraco-clavicular joint. *Nihon Seikeigeka Gakkai Zasshi.* 1980;54:1013–5.
21. Saunders SR. Non-metric skeletal variation. In: Reconstruction of life from the skeleton. vol. 6. New York: AR Liss; 1989. p. 95–108.
22. Hama H, Matsusue Y, Ito H, Yamamuro T. Thoracic outlet syndrome associated with an anomalous coracoclavicular joint. A case report. *J Bone Joint Surg Am.* 1993;75(9):1368–9.

### Author biography

**Sulochana Sakthivel**, Additional Professor

**Nithya Dhakshnamoorthy**, Junior Resident

**Iankathir Sridharan**, Professor

**Sarala Devi K V**, Professor

**Cite this article:** Sakthivel S, Dhakshnamoorthy N, Sridharan I, Devi K V S. An osteological study of the clavicular facet of the coracoclavicular joint. *Indian J Clin Anat Physiol* 2024;11(2):75–78.